Journal of Robotic Surgery
https://doi.org/10.1007/s11701-021-01279-4

ORIGINAL ARTICLE

Feasibility and efficacy of cryoneurolysis analgesia in robotic-assisted thoracoscopic surgery (CARTS): a pilot study

Jivatesh Tung[1] · Rishi Patel[1] · Taufiq Rajwani[1] · Shiwei Han[1] · Neil Hanson[1] · Joel Sternbach[1] · Michal Hubka[1]

Received: 15 April 2021 / Accepted: 4 July 2021
© The Author(s), under exclusive licence to Springer-Verlag London Ltd., part of Springer Nature 2021

Abstract

Opioid therapy has been the mainstay therapy of post-operative pain management in thoracic surgery patients. With the high incidence of chronic pain in thoracic surgery patients and adverse effects of opioids, we examined the safety and efficacy of cryoneurolysis as an adjunct for narcotic-free pain management in robotic-assisted thoracoscopic lobectomies. Ten consecutive patients undergoing robotic-assisted (DaVinci) pulmonary resection and cryoneurolysis were compared to ten patients managed without intraoperative cryoneurolysis. All patients received multimodal pain regimen including paravertebral blocks as per our institutional enhanced recovery pathway. Patients with chronic pain and chronic opioid use were excluded. We compared inpatient and outpatient opioid consumption measured in morphine equivalents (mme), incidence of opioid-free outpatient recovery, and adverse events. The two groups did not differ significantly in terms of baseline demographics. Both inpatient (88.13 vs 26.92 mme) and outpatient (118.5 vs 34.5 mme) use of narcotics were significantly lower in the cryoneurolysis group ($p < 0.05$) with seven of ten patients receiving cryoneurolysis able to recover without the use of opioids in the outpatient setting, compared to two in the control group. One patient reported post-operative neuralgia in each cryoneurolysis and control group. There were no readmissions in either group and mean length of stay was identical at 1.7 days in control group and 1.1 days in experimental group ($p = 0.33$). The use of intraoperative intercostal cryoneurolysis may safely reduce the utilization of outpatient opioids in patients undergoing robotic-assisted thoracoscopic surgery. A randomized controlled trial is warranted to validate these findings in a larger cohort of patients.

Keywords VATS · Cryoneurolysis · Robotic · Lobectomy · Pulmonary resections · Multimodal pain control · Opioid free discharge

Abbreviations

BPM	Beats per minute
IV	Intravenous
MME	Morphine milliequivalents
PO	Per oral
VATS	Video-assisted thoracoscopic surgery

Introduction

For patients undergoing elective thoracic surgery, effective pain management is a crucial component of post-operative recovery. Incision into the pleural cavity through the ribs may induce significant post-operative pain through trauma to the parietal pleura, musculoskeletal tissue and intercostal nerves. Adequate pain control is important in facilitating a patient's ability to participate in early mobilization and respiratory exercises. These are key components of recovery, as inadequately controlled pain is associated with atelectasis, pulmonary infection, and venous thrombosis [1].

Introduction of Video-Assisted Thoracoscopic Surgery (VATS) has lowered the incidence of clinically relevant pain in the first 24 h from 63 to 38% when compared with thoracotomy [2]. Multiple studies have identified thoracic surgery patients as having the highest rate of new persistent opioid use after surgery when compared with other surgical cohorts. 14% of lung cancer resection patients filled opioid prescriptions from 90 to 180 days after surgery [3]. Prospective trials have also demonstrated that severity of acute post-operative pain in the first 2–3 days is an independent predictor of chronic pain at 6 months [4]. While a number of approaches to pain management exist, opioid therapy

✉ Jivatesh Tung
jivatesh.tung@virginiamason.org

[1] Virginia Mason Medical Center, Virginia Mason Hospital, Seattle, WA, USA

Published online: 27 July 2021

remains the mainstay of post-operative pain management, despite the numerous adverse events associated with its use.

Cryoneurolysis was first described by Lloyd et al. in the 1970s and has since been reported in the adult population in post herniorrhaphy neuropathic pain, thoracic trauma, chronic thoracic pain, orthopedic surgery as well as pediatric thoracic surgery [5–8]. It has been reported as not only safe, but also an efficacious treatment modality in both pediatric and adult patients. Prior studies have demonstrated that patients undergoing cryoneurolysis had decreased length of stay (LOS) and decrease in mean total post-operative intravenous opioid use [5]. While thoracic epidural anesthesia reduces utilization of opioids, the effects are short term. There is a paucity of cryoneurolysis data from the adult population undergoing robotic-assisted thoracoscopic surgery. As such, there is a critical need to improve non-opioid analgesia techniques and facilitate recovery in thoracic surgery patients.

Cryoablation works by freezing the nerve axon thereby preventing transmission of electric signal resulting in analgesia. Wallerian degeneration commences from the point of injury toward the nerve endings. Meanwhile, the nerve "scaffold" consisting of epineurium and perineurium remains intact allowing regeneration [9]. Nerve regeneration takes place at 1–3 mm/day and should conclude in a few months [10].

We examined the efficacy and safety of adding intercostal cryoneurolysis to a multimodal pain management pathway, with the goal of achieving opioid-free outpatient recovery in patients undergoing robotic pulmonary resection.

Materials and methods

Clinical data for twenty patients undergoing robotic-assisted pulmonary resections with and without cryoneurolysis between October 2019 and April 2020 were recorded in an IRB approved prospective thoracic clinical database (IRB 13087) and retrospectively reviewed. Patients with a history of prior thoracic surgery, allergies to any component of the multimodal analgesic medications, history of chronic pain or history of chronic opioid use were excluded. All operations were performed by a single surgeon (MH) using the DaVinci Xi surgical system (DaVinci: Intuitive Surgical, Inc., Sunnyvale CA, USA) and standard, consistent port placement in the eighth and tenth intercostal spaces. Cryoneurolysis was performed using the Frigitronics CE-82 cryosurgical system and reusable probe with outer diameter of 1.9 mm and length of 900 mm (Frigitronics, CooperSurgical, Inc., Trumbull, CT, USA) placed via a 12 mm plastic assist port (Airseal, CONMED, Utica, NY, USA). The probe tip was placed adjacent to the inferior surface of rib corresponding to the targeted intercostal nerve for two minutes per intercostal space at negative 80 degrees Celsius (Fig. 1).

All patients were treated with a standard multimodal pain regimen that included preoperative administration of acetaminophen (975 mg PO) and gabapentin (300 mg PO). Intraoperatively, patients receive fentanyl (25 mcg IV) for heart rate increase of 10 bpm and systolic blood pressure increase of 20 mm Hg. Paravertebral nerve blocks covering four rib spaces using a total of 30 cc of 0.25% bupivacaine with epinephrine are performed under direct visualization at the end of each operation. Post-operative analgesia includes scheduled acetaminophen (975 mg PO every 6 h), gabapentin (600 mg PO at bedtime), celecoxib (200 mg PO every 8 h); with as needed oxycodone (5–10 mg PO every 4 h). Outpatient regimen at discharge included acetaminophen 650 mg PO every 6 h, Meloxicam or Ibuprofen (15 mg PO daily or 600 mg PO every 6 h, respectively), and rescue oxycodone (5–10 mg PO every 4 h as needed).

The electronic medical record was interrogated for oxycodone intake, standardized to oral morphine equivalents, and analyzed using Google Sheets (Google, Alphabet Inc., Mountain View, CA, USA). Patient clinical characteristics and clinical outcomes were compared. Outpatient opioid use, need for a second prescription and any adverse events were evaluated at the time of in person follow-up or telephone interviews for three months post operatively.

Statistical analyses and data visualization were performed using Prism software, version 8.0 (GraphPad Software Inc., La Jolla, CA). The significance of difference between groups within figures was confirmed using unpaired *t* tests

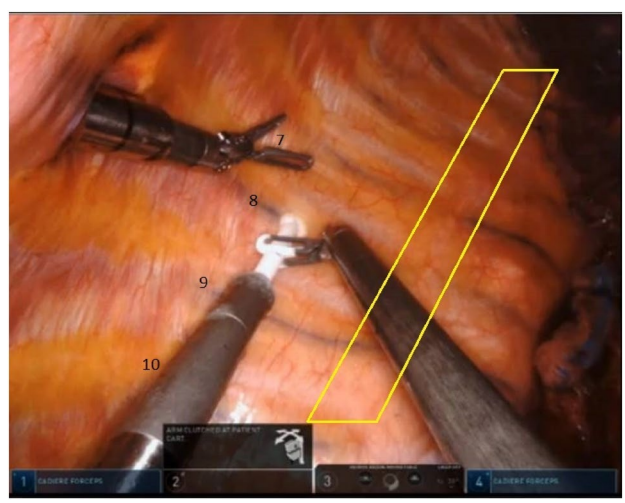

Fig. 1 Technique for cyroneurolysis. Displayed is a right thoracic cavity at the conclusion of a lobectomy. The most posterolateral trocar is located at top left of picture. Numbers represent targeted intercostal nerves. Yellow box outlining sympathetic nerve chain. Robotic arms 1 and 4 utilizing Cadiere forceps to assist in probe application. Probe inserted via 12 mm assist port in the 10th intercostal space

Table 1 Clinical characteristics

Characteristics	Control group ($n=10$)	Cryo group ($n=10$)	p value
Age, years	67.4 ± 6.1	69.4 ± 8.1	0.54
Charlson comorbidity score	5 ± 1.2	6.2 ± 2.3	0.15
FEV1, %	92.6 ± 16.3	93.4 ± 13	0.90
Length of stay, days	1.7 ± 1.3	1.1 ± 0.3	0.33

Values are shown as mean ± SD or number

Table 2 Adverse events

	Control group ($n=10$)	Cryo group ($n=10$)
Total number of complications, n	5	2
Atrial fibrillation	1	0
Air leak (requiring chest tube)	2	0
Chest wall hematoma	0	1
Intercostal neuropathic pain	1	1
Urinary retention	1	0

or Mann–Whitney test. Two-sided $p < 0.05$ was considered significant.

Results

Twenty opioid-naïve patients undergoing a robotic-assisted pulmonary resection in the Thoracic Surgery department at Virginia Mason Medical Center were recruited. Among them, ten received the standard enhanced recovery pathway alone (control group) and ten received both the enhanced recovery pathway with the addition of intercostal cryoneurolysis (cryo group). Median age was 68.5 years in the control group and 70 years in the cryo group. Both experimental and control groups demonstrated similar clinic characteristics (Table 1).

Overall, the post-operative adverse event rate was 50% in the control and 20% in the cryo groups, respectively (Table 2). There were no readmissions or other reinterventions in either cohort. One patient in the control group and one patient in the study group experienced neuralgia of the intercostal space and the ipsilateral anterior upper quadrant of the abdominal wall.

There was a significant difference in both inpatient and outpatient opioid consumption between the two groups (Fig. 2). The mean utilization of opioids in the inpatient setting was 88.13 mme in the control group and 26.92 mme in the cryo group. Mean opioid consumption in the outpatient setting was 118.5 mme in the control group, compared to 34.5 mme in the cryo group. 70% percent of all cryoneurolysis patients used no opioid medication after being discharged, compared to 20% of the control group. 50% of patients in the control group required a second narcotic prescription compared to 20% of patients who underwent cryoneurolysis. There were no patient readmissions from either group.

Discussion

While there is less risk of new persistent opioid use in patients undergoing minimally invasive thoracic surgery compared to open thoracotomy, two thirds of these patients still require post-operative opioids which could lead to persistent opioid use [11]. This pilot study demonstrates a significant reduction in perioperative opioid consumption using cryoneurolysis for robotic-assisted thoracoscopic surgery.

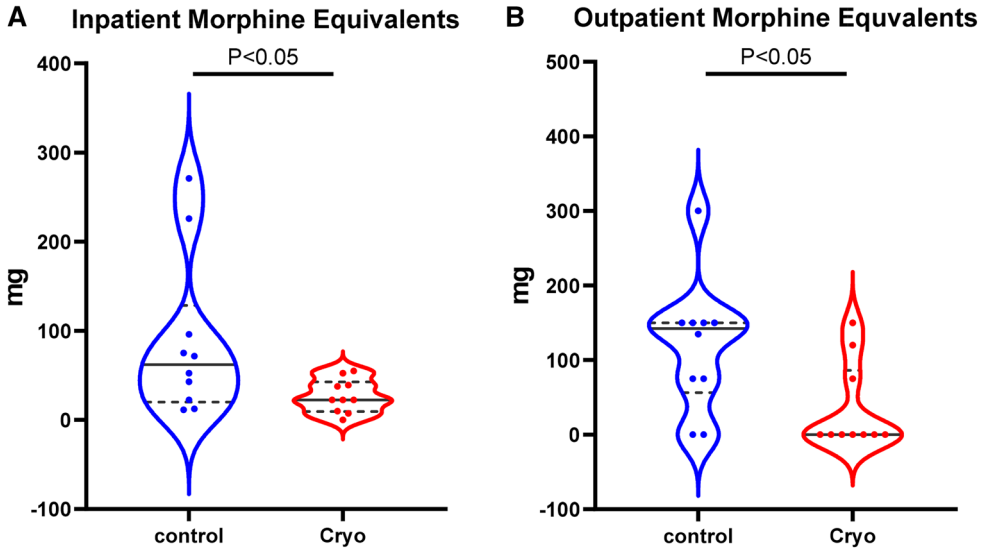

Fig. 2 Inpatient (**A**) and Outpatient (**B**) Opioid Consumption. Data are expressed in oral/IV morphine consumption (mg)

Moreover, the described cryoneurolysis technique appears to be safe, with only one patient experiencing transient chest wall neuralgia that resolved following treatment with one month of gabapentin therapy.

Our findings correlate well with the current published data especially in the Children's study discussing cryoneurolysis for Nuss procedures which demonstrated reduced IV opioid use to approximately 30% of control as well as reduced length of stay by 2 days. Nuss procedure cyroneurolysis follow-up extended to 1 year and did not show increased incidence of neuropathic pain or neuromas, however reported numbness which recovered in all patients at the 1-year mark. Their study was also limited by a small sample size of 20. In addition, multiple case reports of VATS cryoneurolysis in rib fractures resulting in reduced opioid requirement have been published in trauma literature. Prospective randomized data in general but especially in Robot-Assisted thoracoscopic surgery are lacking.

The adoption of any new technique needs to be addressed in the context of cost as related to outcomes. The technique described uses a Fridgitronix system, which includes a reusable probe. This offers the distinct advantage of no added variable cost from disposables after the initial fixed cost investment, unlike previous reports utilizing systems with disposable components [5].

This pilot study has several limitations. Its primary goal was to evaluate the use of outpatient opioid use specifically. The pain burden as evaluated by pain scores was not evaluated. Furthermore, quality of life and subjective recovery perceptions were not objectively recorded. We believe that an objective surrogate of decreased opioid use is an important finding. Pain scores in patients may not be clinically relevant due to the subjective nature of the measurement. This pilot study also includes only a limited sample size and as such conclusive relationships between cryoneurolysis and narcotic-free recovery cannot be definitively demonstrated. However, we are encouraged by these preliminary findings.

Conclusion

With the high prevalence of persistent pain and chronic opioid use in thoracic surgery patients, we believe cryoneurolysis is a promising and safe adjunct to existing multimodal pain pathways as demonstrated in our pilot study. Prospective, randomized studies with larger cohorts are required to validate the efficacy of cryoneurolysis in reducing postoperative pain following robotic thoracoscopic pulmonary resection.

Funding No formal funding was provided. Cryoablation device and probes were re-used after proper sterilization.

Declarations

Conflict of interest The authors have no disclosures or conflict of interest to report.

Ethical approval IRB approval-13087.

Informed consent For this study, informed consent was obtained from all patients.

References

1. Khandhar SJ, Schatz CL, Collins DT, Graling PR, Rosner CM, Mahajan AK, Kiernan PD, Liu C, Fernando HC (2018) Thoracic enhanced recovery with ambulation after surgery: a 6-year experience. Eur J Cardiothorac Surg 53(6):1192–1198. https://doi.org/10.1093/ejcts/ezy061
2. Bendixen M, Jørgensen OD, Kronborg C, Andersen C, Licht PB (2016) Postoperative pain and quality of life after lobectomy via video-assisted thoracoscopic surgery or anterolateral thoracotomy for early stage lung cancer: a randomized controlled trial. Lancet Oncol 17:836–844
3. Brescia AA, Harrington CA, Mazurek AA et al (2019) Factors associated with new persistent opioid usage after lung resection. Ann Thorac Surg 107:363–368
4. Bayman EO, Parekh KR, Keech J, Selte A, Brennan TJ (2017) A prospective study of chronic pain after thoracic surgery. Anesthesiology 126:938–951
5. Graves CE, Moyer J, Zobel MJ, Mora R, Smith D, O'Day M, Padilla BE (2019) Intraoperative intercostal nerve cryoablation during the Nuss procedure reduces length of stay and opioid requirement: a randomized clinical trial. J Pediatr Surg 54(11):2250–2256. https://doi.org/10.1016/j.jpedsurg.2019.02.057
6. Hegg RM, Kurup AN, Schmit GD, Weisbrod AJ, Atwell TD, Olivier KR, Moynihan TJ, Callstrom MR (2014) Cryoablation of sternal metastases for pain palliation and local tumor control. J Vasc Interv Radiol 25(11):1665–1670. https://doi.org/10.1016/j.jvir.2014.08.011
7. Koethe Y, Mannes AJ, Wood BJ (2014) Image-guided nerve cryoablation for post-thoracotomy pain syndrome. Cardiovasc Intervent Radiol 37(3):843–846. https://doi.org/10.1007/s00270-013-0718-8
8. Bittman RW, Peters GL, Newsome JM, Friedberg EB, Mitchell JW, Knight JM, Prologo JD (2018) Percutaneous image-guided cryoneurolysis. Am J Roentgenol 210(2):454–465
9. Piccioni F, Segat M, Falini S, Umari M, Putina O, Cavaliere L, Ragazzi R, Massullo D, Taurchini M, Del Naja C, Droghetti A (2018) Enhanced recovery pathways in thoracic surgery from Italian VATS group: perioperative analgesia protocols. J Thorac Dis 10:S555–S563
10. Trescot AM (2003) Cryoanalgesia in interventional pain management. Pain Phys 6(3):345–360
11. Obuchi T, Yoshida Y, Moroga T et al (2017) Postoperative pain in thoracic surgery: re-evaluating the benefits of VATS when coupled with epidural analgesia. J Thorac Dis 9:4347–4352

Publisher's Note Springer Nature remains neutral with regard to jurisdictional claims in published maps and institutional affiliations.